

## Congenital Hydrometrocolpos in a 2 Months Old Indian Infant Presented as Dysuria: A Case Report

Karan Soni MBBS and Amrit L Soni MD\*

Department of Pediatrics, Ahalia Hospital Musaffah, Abu Dhabi, UAE.

### \*Correspondence:

Amrit L Soni, P.O. Box 2419, Hamdan St. Abu Dhabi, UAE, Tel: +971-551246106, E-mail: amritsony@gmail.com.

Received: 30 September 2018; Accepted: 23 October 2018

**Citation:** Karan Soni MBBS, Amrit L Soni MD. Congenital Hydrometrocolpos in a 2 Months Old Indian Infant Presented as Dysuria: A Case Report. Cancer Sci Res. 2018; 1(4); 1-4.

### ABSTRACT

**Background:** Hydrometrocolpos due to vaginal atresia is a rare congenital anomaly characterized by an abdominal mass; girls with this anomaly are prone to develop obstructive uropathy due to compression of bladder and/or urethra.

**Case:** We report the case of a two-month-old girl who presented with an abdominal mass and dysuria. She was found to have a lower vaginal atresia and hydrometrocolpos by MRI. She was successfully treated surgically by reconstruction of vagina and drainage of 100 ml serosanguinous fluid.

**Summary and Conclusion:** Early diagnosis and surgery reduces the incidence of complications such as infection, rupture and renal failure. Diagnosis may be suspected prenatally by ultrasonography and confirmed postnatally by magnetic resonance imaging.

### Keywords

Hydrometrocolpos, Congenital, Hydronephrosis, Neonatal, MRI.

### Introduction

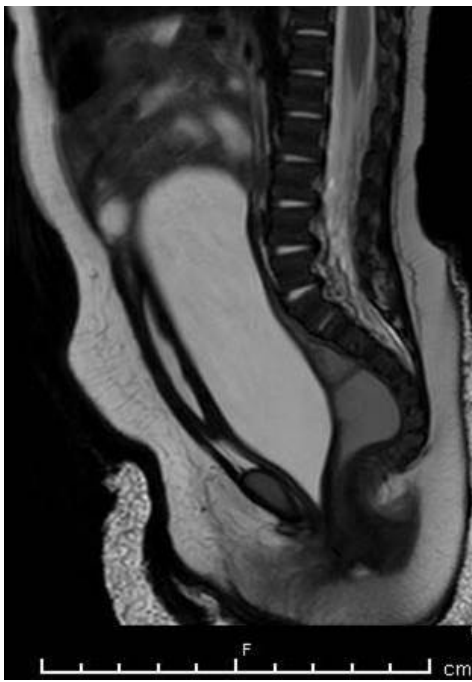
Hydrometrocolpos is a rare condition in which the uterus and the vagina are grossly distended with a retained fluid other than pus or blood. It may present during the neonatal period or later at puberty as an abdominal mass or obstructive uropathy due to compression of bladder and/or urethra [1,2]. Imperforate hymen and lower atresia of vagina are most common causes of congenital hydrometrocolpos [3]. Most cases reported earlier were stillbirths and were diagnosed only on autopsy [1]. Antenatal diagnosis is now possible with the advent of ultrasound [4-6]. An early diagnosis and speedy management is the key to survival [1].

### Case

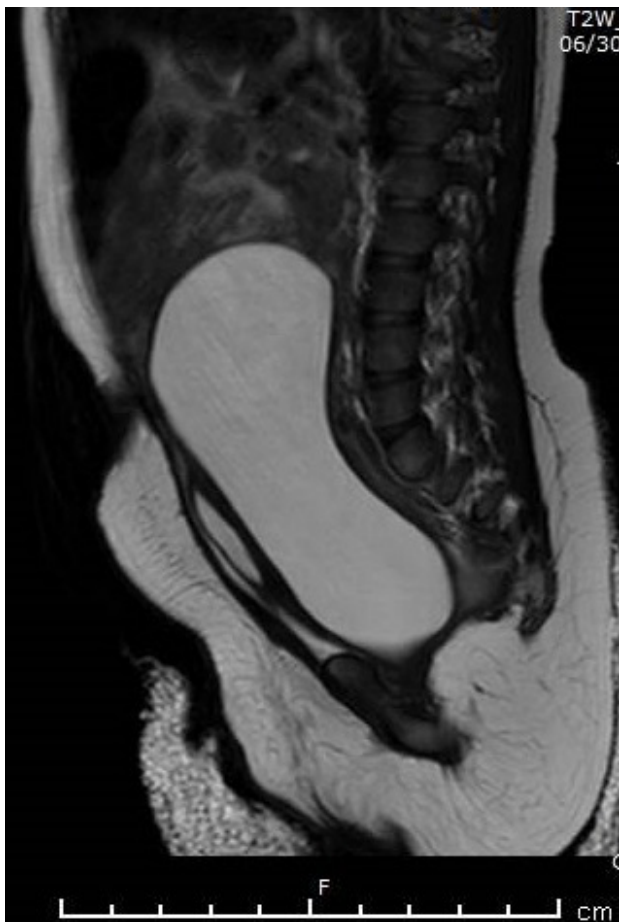A two month old female baby presented to us with crying while passing urine for 1 week. She was born at full-term by normal vaginal delivery to an Indian mother at other hospital in Abu Dhabi. Antenatal period was uneventful except the fetal ultrasound reported intra-abdominal cyst in late pregnancy. There was no oligohydramnios or any other anomaly. Birth weight was 3.1 kg.

APGAR score was normal. Postnatal ultrasound was reported as? ovarian cyst. Prior to presentation, the baby was doing well and was on exclusive breastfeeding. On examination baby was well looking, well thriving, not dysmorphic, urine stream was normal and a large firm mass was felt in the lower abdomen. Other examination was normal. Laboratory investigations like CBC, urinalysis, renal functions were normal. Abdomino-pelvic ultrasound reported a huge cystic mass with mild bilateral hydronephrosis.

MRI done with contrast under general anesthesia showed a large well defined lobulated craniocaudally elongated pelvo-abdominal lesion showing T2W hyperintense and T1W hypointense signal was noted with its inferior third predominantly in the midline (Figures 1-3). This lesion measured about 9.5 (craniocaudal) x 6.0 (transverse) x 3.2 (anteroposterior) cm and showed a inferiorly beaked orientation between the urethra anteriorly and rectum/anal canal posteriorly (in the presumed location of the uterus/vagina) with non-visualization of the uterus, cervix and vagina separately (Figure 1); features were suggestive of hydrometrocolpos with thinning of the uterine myometrium and cervical stroma. The inferior beaked margin of the hydrometrocolpos was located at the level of the inferior margin of the pubic symphysis (Figure 1).

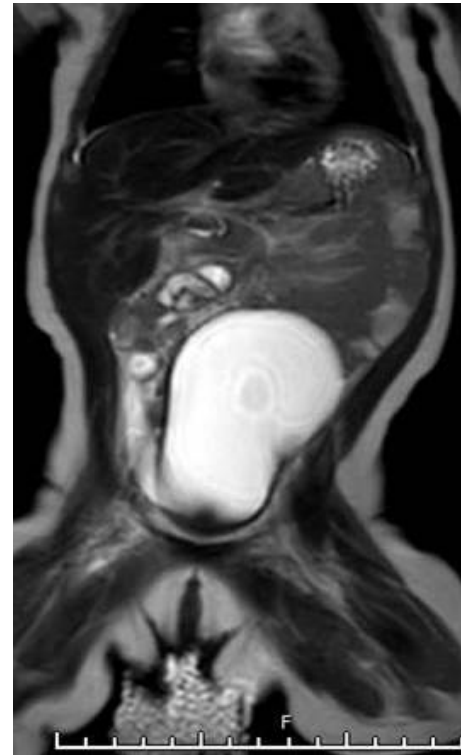


**Figure 1:** MRI T2W sagittal view showing 9.5 x 3.2 cm large, well defined, lobulated, craniocaudally elongated, pelvo-abdominal hydrometrocolpos; showing fluid signal with an inferiorly beaked orientation between the urethra anteriorly and rectum/anal canal posteriorly. The inferior extent of the beaked portion of the hydrometrocolpos was located at the level of inferior margin of pubic symphysis.



**Figure 2:** MRI T2W sagittal view showing 9.5 x 3.2 cm large, well defined, lobulated, craniocaudally elongated, pelvo-abdominal hydrometrocolpos. The urinary bladder appeared craniocaudally elongated and compressed against the anterior abdominal wall.

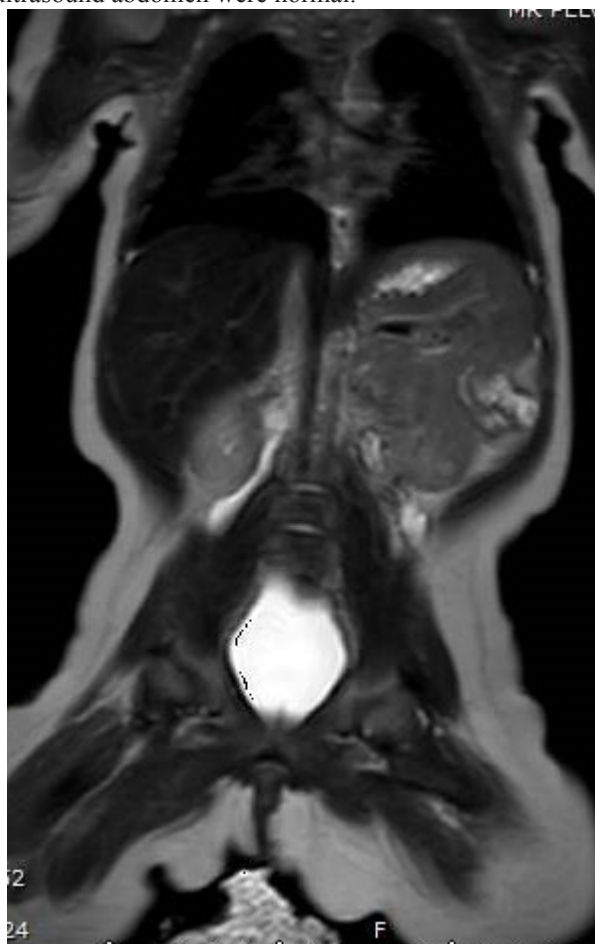
No significant enhancing internal septations or solid nodules were noted within the large fluid signal lesion on post contrast images. Rest of the vagina below the level of the inferior beaked portion could not be adequately commented upon in the obtained images. The urinary bladder appeared craniocaudally elongated, compressed against the anterior abdominal wall and was mildly displaced to the right side of the midline by the large hydrometrocolpos (Figure 3).



**Figure 3:** MRI T2W coronal view showing 9.5 x 6.0 cm large, well defined, lobulated, craniocaudally elongated, pelvo-abdominal hydrometrocolpos compressing adjacent viscera.

Mild prominence of the pelvicalyceal system was noted in bilateral kidneys with associated mild-to-moderate dilatation of the proximal and middle third of the ureters (Figure 4). Urethra appeared stretched and craniocaudally elongated along the anterior margin of the hydrometrocolpos (Figure 4). Both kidneys showed normal enhancement and prompt excretion on post-contrast images. Both ovaries could not be adequately visualized in this study. The rectum and anal canal appeared unremarkable. No significant free fluid was noted in pelvis. The visualized lumbar spine showed normal appearance of the vertebral bodies and sacrum. The visualized lumbar spinal cord appeared normal in thickness and terminated normally at L1 vertebral level. The soft tissues showed no significant abnormalities. The visualized liver, gallbladder and spleen appeared normal in location, size and signal with normal post contrast enhancement. No significant

focal lesions were demonstrable in these solid organs. The baby was operated on by a Pediatric surgeon who found lower vaginal atresia for which reconstruction surgery and drainage of 100 ml serosanguinous fluid was done. The baby became free from urinary symptoms after the surgery. The follow-up examination and ultrasound abdomen were normal.



**Figure 4:** MRI T2W coronal view showing hydrometrocolpos and mild prominence of the pelvicalyceal system in bilateral kidneys.

## Discussion

Hydrometrocolpos refers to the distension of the uterus and the vagina with a fluid other than blood or pus, usually in presence of a distal obstruction. When only the vagina or the uterus is distended independently, it is called hydrocolpos or hydrometros respectively. Usually it is the distension of both, the vagina and the uterus; the main brunt being borne by the vagina [1]. Congenital hydrometrocolpos is a rare event with an incidence of about 0.006 % in live births [3]. This condition may be caused by congenital malformations of the genital tract such as vaginal atresia, transverse vaginal septum and imperforate hymen. The most frequent cause is imperforate hymen which presents as a soft oval mass at the vaginal opening differentiating it from vaginal atresia in which no such mass is visible at the vaginal orifice [3-6]. Hydrometrocolpos may also be associated with the McKusick–Kaufman syndrome, an autosomal recessive disorder characterized by vaginal atresia with hydrometrocolpos, polydactyly, congenital heart defects and non-

immune mediated hydrops fetalis [1]. In our case, vaginal atresia was the cause of hydrometrocolpos. Vaginal atresia or imperforate hymen is a result of the hymen failing to rupture during the eighth week of gestation; it may be an isolated abnormality or associated with other malformations, such as imperforate anus, bifid clitoris, polycystic kidney.3 Hydrometrocolpos may remain asymptomatic as an abdominal mass or may cause Complications like urinary tract obstruction, renal failure, repeated urinary tract infections, rupture and peritonitis. Urinary tract obstruction can lead to oligohydramnios antenatally. Sepsis leading to death can occur secondary to either urinary tract infection or rupture and secondary peritonitis [1-3]. Urinary stasis and acute renal failure are due to obstructive uropathy by compression [7,8].

Diagnosis of hydrometrocolpos can be made prenatally or postnatally using ultrasonography and magnetic resonance imaging [1-6]. Early diagnosis reduces the incidence of complications [1,7,8]. Differential diagnosis of a perinatally identified abdominal mass includes ovarian cysts, intra-abdominal sacrococcygeal teratoma (type IV), neuroblastoma, mesoblastic nephroma, bowel duplication, genito-urinary anomalies and anterior sacral meningocele [3].

Treatment is according to the cause. If hydrometrocolpos is caused by imperforate hymen, hymenectomy has proved to be an adequate, conservative treatment. Vaginal reconstruction surgery is done for vaginal atresia as was in our case [1,3].

## Conclusion

Neonatal hydrometrocolpos is a rare condition which requires a high index of suspicion for diagnosis [1]. Diagnosis may be suspected prenatally by ultrasonography and confirmed postnatally by magnetic resonance imaging [1-6]. Early diagnosis reduces the incidence of complications such as infection, rupture and renal failure [1,7].

## Acknowledgments

This case has been presented as an E-poster and video presentation in the conference “21st World Congress on Radiology and Cancer Research” Aug 27-28, 2018 in Toronto, Ontario, Canada.

## References

1. Hanna K, Sharma S, Gupta DK. Hydrometrocolpos etiology and management: past beckons the present. *Pediatr Surg Int*. 2018; 34: 249-261.
2. Messina M, Severi FM, Bocchi C, et al. Voluminous perinatal pelvic mass: a case of congenital hydrometrocolpos. *J Matern Fetal Neonatal Med*. 2004; 15: 135-137.
3. Vitale V, Cigliano B, Vallone G. Imperforate hymen causing congenital hydrometrocolpos. *J Ultrasound*. 2013; 16: 37-39.
4. Winderl LM, Silverman RK. Prenatal diagnosis of congenital imperforate hymen. *Obstet Gynecol*. 1995; 82: 655-656.
5. Bhargava P, Dighe M. Prenatal US diagnosis of congenital imperforate hymen. *Pediatr Radiol*. 2009; 39: 1014-1017.
6. Tseng JJ, Ho JY, Chen WH, et al. Prenatal diagnosis of isolated fetal hydrocolpos secondary to congenital imperforate hymen.

- 
- J Chin Med Assoc. 2008; 71: 325-328.
7. Sharifiaghdas F, Abdi H, Pakmanesh H, et al. Imperforate hymen and urinary retention in a newborn girl. J Pediatr Adolesc Gynecol. 2009; 22: 49-51.
8. Aygun C, Ozkaya O, Ayyildiz S, et al. An unusual cause of acute renal failure in a newborn: hydrometrocolpos. Pediatr ephrol. 2006; 21: 572-573.