

High- Performance Otoplasty Technique

Marcelo S. Assis*

Member of Brazilian Society of Plastic Surgery.

Member of International Society of Aesthetic Plastic Surgery.

*Correspondence:

Marcelo S. Assis, Coordination of Plastic Surgery, PROJETO ORELHINHA, 55 Oriente St Chácara da Barra, Campinas, SP, Brazil, Tel: +55 19992530004.

Received: 20 April 2019; Accepted: 15 May 2019

Citation: Marcelo S. Assis. High- Performance Otoplasty Technique. Surg Res. 2019; 1(1): 1-4.

ABSTRACT

Background: Edward Talbot Ely (1850-1885) lived a tragically short life of 35 years, but at the age of 31 years, in 1881, he recorded the landmark case of the first otoplasty in the medical literature [10]. Prominent ears “Dumbo Ears” are probably the ear deformity that most people are aware of. Is a very common problem, and according to literature occurs in 5 % of the Caucasian population [1], causing bullying and reducing self-esteem, also leading to serious consequences for individuals social integration [2]. This paper describes a unique approach based on other available techniques developed to increase productivity and enhance performance.

Methods: In 2014, a non-government organization was created specializing in Otoplasty for patients as young as 7 years old who have an aesthetical complaint or is a victim of bullying. Our technique corrects the 3 parts of the ear. The surgeries are performed in an outpatient setting with a minimal charge for material and medication. The procedure is done with local anesthesia and light sedation allowing maximum comfort for the patient and the surgeon. There is no hospitalization.

Results: From 2014 to 2017, we have performed 4.000 surgeries following the High-Performance Protocol. Patients only payed U\$600,00 for total cost. The High-Performance Protocol can be reproduced any time despite location, surgeon or anesthetist. The average cost for material and medication for these surgeries is US\$ 76,90. The average surgical time is 45 minutes. Of these 4.000 surgeries, we had a recurrence rate of 3%, and even a lower rate of complications such as hematomas, infections, skin/cartilage necrosis, allergic reaction, hypertrophic/keloid scar, cartilage irregularity and late sensitivity changes.

Conclusion: The High-Performance Protocol emerges as an option to increase accessibility for Otoplasty by lowering the average cost, surgical time and recurrence. This protocol will allow surgeons to increase the number of low income patients who need this surgery and help prevent bullying in this population.

Keywords

Ear correction, Otoplasty, Low Cost Technique, High-Performance, New proposal technique.

Introduction

Prominent ears are the result of cartilage changes, often bilateral, are normally caused by genetic inheritance, but can also occur due the fetal position [3]. Prominent ears should not cause bullying, but with the increasing people exposure on social networks, especially through sharing of the popular selfies, some individual peculiar and striking characteristics often become the cause of jokes, humiliation and bullying [2]. Prominent ears are one of the main

causes among physical distinctions[6]. Since Dieffenbach in 1845 up to Fritsch in 1992 several ear corrective surgery techniques were developed [10]. All of them have advantages as execution time, learning curve, and particular weak and strong points[2] [3]. The High Performance Otoplasty Technique here described is a combination of the best of many others available, specifically focusing and aiming to increase surgical procedure productivity, as the fundamental pillar of a major system, here named Medical Lean, in the particular field of nongovernment organization project. This so named, Medical Lean, is based on the known TPS – Toyota Production System[5] and also acts on six stages of an optimization pyramid (Figure 1).

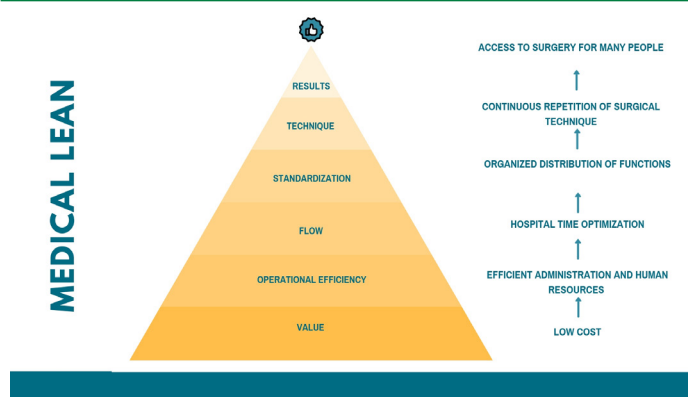


Figure 1: Medical Lean pyramid optimization.

Patients and Methods

Ear correcting surgery is seven years old, and in our approach is based on the feeling of discomfort due to prominent ears, affecting the social life. It is defined as a deformity of the up, down or middle third, or even all of the ear in association with a scaphoconchal clearance higher than two centimeters. Additional focal deformities such as prominent top edge and lobe projection are also treated. All patients are examined by trained plastic surgeons, which perform the physical ear observation and argue about the patient expectations. Information is recorded in a data sheet later filed in a computerized Service Management System. One individual sedation kit is assigned to each patient. Surgical kit includes 01 curve Kelly clamp, 01 needle holder, 01 Adson clamp, 2 bacaus and 01 straight iris scissors. Material and medicine used include one 70 cm monocryl wire 4.0 by surgery, and anesthetic solution of 20 ml saline solution, 5 ml xylocaine at 2%, 3 ml of marcaine at 0,5% and 0,3 ml of adrenalin. For the curative, simple cotton for the cartilage mold is used, one sterile gauze pack, one 15 cm cotton ball, and one 10 cm width tubular orthopedic mesh to be applied as a protective cap (Figure 2).

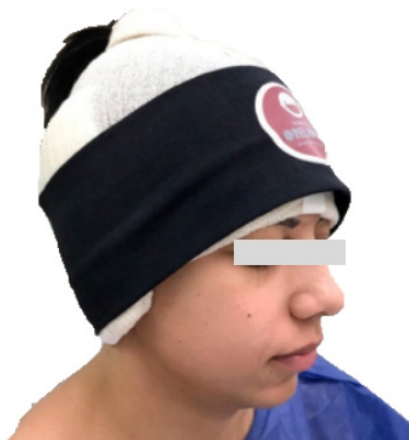

Figure 2: Standardized Curative Cap.

Child sedation is done using one polyurethane cannula with side injector, one oxygen catheter, one 10 ml syringe, one 30 x 0,8 mm needle, 2 ml of O₂/ minute, 250 ml of saline solution, 1 ml of 10 mg diazepam, 2 ml of midazolam 5mg/5ml, 1 ml of 100 microgram fentanyl, and 2 to 3 ml of 10 mg/ml propofol, if necessary.

Adults sedation protocol includes one polyurethane cannula with side injector, one oxygen catheter, one 10 ml syringe, one 30 x 0,8 mm needle, 2 ml of O₂/minute, 500 ml of saline solution, 2 ml of 10 mg diazepam, 2 ml of midazolam 5 mg/ml, 2 ml of 100 microgram fentanyl, 2ml of 10 mg bromopride, 2 ml of 1g dipyrone.

There is no need for antibiotic therapy because the surgery is a clean procedure executed in an ambulatory environment. The surgeries are performed in hospitals endowed with adequate structure and patients monitored until their hospital discharge. Surgery takes no more than 45 minutes after what the patients are taken to a post-anesthetic rest area for about 30 minutes. After that, they are taken to a room for light feeding. Finally, patients are re-evaluated before hospital discharge.

All patients receive a standard bandage that doesn't go through the neck and the instructions not to take them off before 96 hours. They also receive a medical prescription for antibiotic, analgesic, antiseptic, and instructions for local care and asepsis. Additional review medical appointments are scheduled for thirty and ninety days after. For the case of any complications, online medical support is available. If required the patients are forwarded to a face-to-face assessment.

Surgical Technique

1 Step – Ear Marking

Before starting the surgery, the patient is questioned about his main concern and claim, and the cartilage areas that will be worked on are marked, with the patient sitting and at dorsal decubitus. The bi-digital maneuver, in order to make it possible to draw a spindle for later resection (Figure 3). The anti-helix projection is then marked with a surgical pen respecting local anatomy, right after the bidigital maneuver intended to fit the ears in normal position next to head. The exceeding auricular concha is marked after.

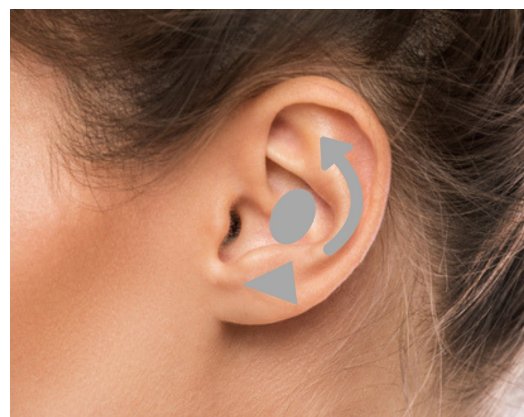

Figure 3: Cartilages markings.

The retro-auricular skin spindle is marked, observing the projection line of the previous anti-helix and lower edge, with auricular groove marking done in between the ear and mastoid.

2 Step – Infiltration with local anesthetic

The use of local anesthesia with infiltration restricted to the retro-

auricular spindle only, with blocking of the great auricular nerve as practiced in the HPO Technique, allows a lower surgical time in comparison with conventional techniques, leading to a mean surgical time of 45 minutes for both ears. This step uses 20 ml of saline solution, 5 ml of lidocaine at 2% with a vasoconstrictor, 3 ml of marcaine at 2 % without vasoconstrictor and 0, 3 ml of adrenalin.

3 Step – Surgical Procedure

The HPO Technique consists of three stages of cartilage treatment according to each individual indicated needs. Anti-helix cartilage treatment: parallel condrotomy are performed on cartilage islands with a thickness of 2 mm, in half moon shape, following the posterior edge of the ears, with total depth until the dermis. The objective is to mold the area in an inverted U shape, the first island being the side wall, the second being the roof, and the third island being the medial wall, so forming a new anti-helix projection (Figures 4a and 4b). This maneuver corrects prominences of ear's upper third. The differential of the HPO Technique is that it uses no type of cartilage stitches like Mustardé and Furnas [8,9], that may cause discomfort and chronic pain or the extrusion of un absorbable sutures.

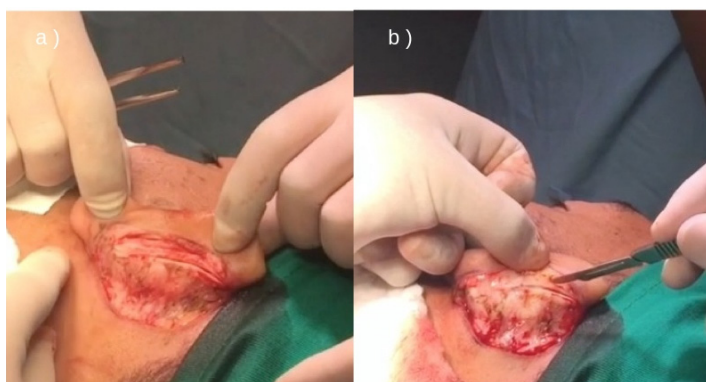


Figure 4: Intraoperative vision: a) Parallel condrotomy on islands, b) Preparation of 2 mm parallel cartilage equidistants for the neoformation of anti-helix.

4 Step - Concha Cartilage Treatment

After reinforcement of the anesthetic blocking of the great auricular nerve and anterior infiltration of the concha for skin detachment, the total incision of the ear (a) (b) shell spindle is done under the previous marking, on the justa perichondrial plan, removing the excess of concha cartilage which projects the ears forward (Figure 5). The skin doesn't show a deep detachment, that will be only until the down edge of the spindle to be removed, so causing less pain and loss of area sensitivity. Not one fixation stitch of the concha will be used.

5 Step - Helix Treatment

When the patient shows an anterior projection of the earlobe, checkered incisions are performed on the helix, in order to break its spring effect and to draw back the ear lower third. If there is lobe skin excess, then the incision technique applied is the Y or fish tail (Figure 6).

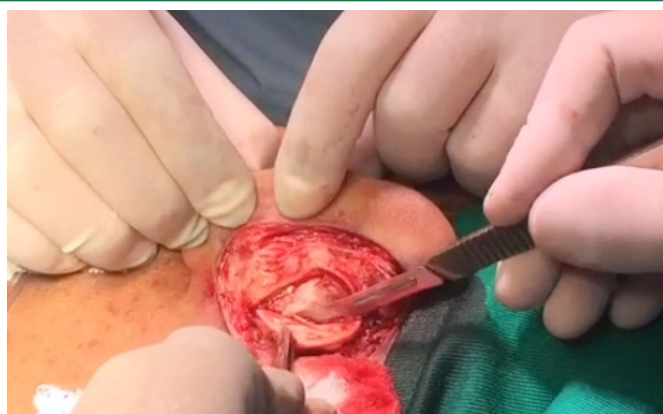

Figure 5: Removal of auricular concha justa-perichondrial spindle according to prior marking.

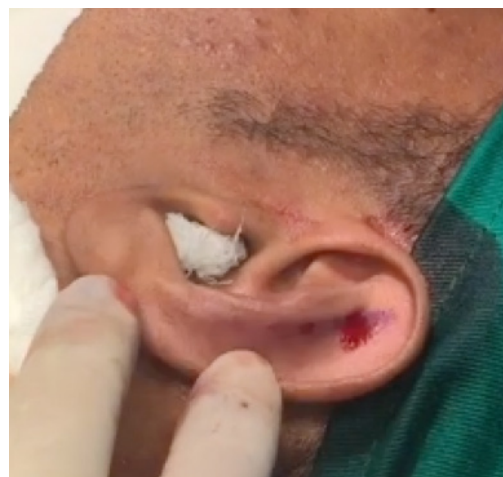

Figure 6: Surgery finished with neo-formation of the anti-helix, auricular concha in position and parallel helix or middle third and superior.

6 Step – Skin Synthesis

After proper review of the hemostasis, one reinforcement stitch is done on the ear's upper third, using monocryl 4.0 suture, between the cartilage over the islands and at the mastoid base, with the purpose of reducing recurrence of the anterior projection ear upper third that normally occurs in the cases of telephone ears or in C shape. The skin synthesis is done with one intradermal stitch of monocryl 4.0.

7 Step - Cotton Mold and Bandage Helmet

A standard bandage is kept applied for 96 hours after the hospital discharge, with a moist cotton mold at the anti-helix and at the shell, with the purpose of stabilizing the sculpted cartilages and to contain the local edema. Additionally, a cotton ball is put under the ears for better protection. This bandage was developed in a way that it doesn't go through the neck, for better acceptance and higher comfort after surgery (Figure 2).

After the bandage helmet removal the patient is oriented to use a compressive bandage, ballerina type, only at night when sleeping, during 30 days after hospital discharge. Final result examples are shown below (Figures 7, 8 and 9).

J.T.L.S. 17 years old. Operated in 2014

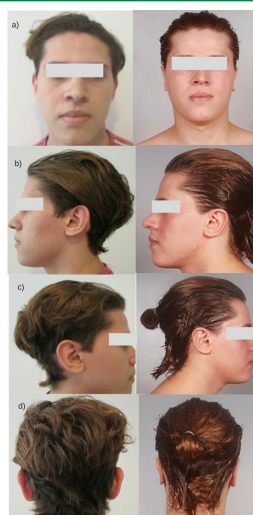

Figure 7: Follow up of 4 years.

E.F.S. 33 years old. Operated in 2017

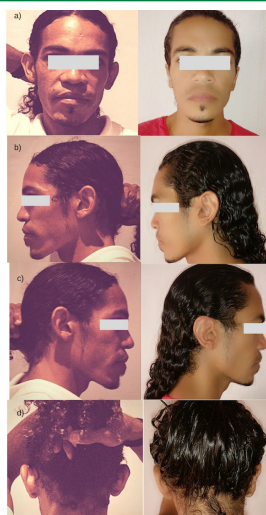

Figure 8: Follow up of 3 years.

R.E.S.C. 40 years old. Operated in 2016

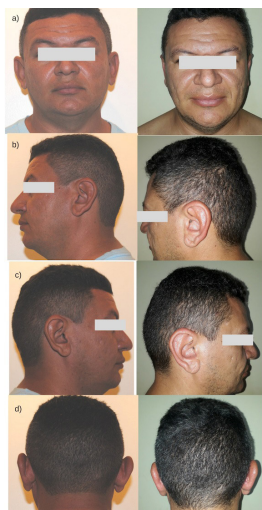


Figure 9: Follow up of 2 years.

A.B.N.S. 21 years old. Operated in 2015

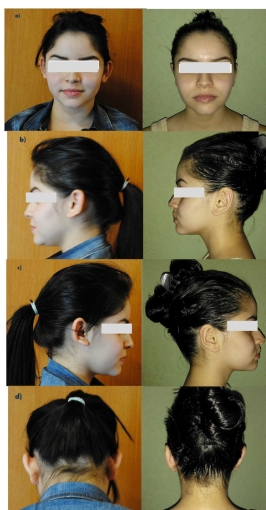

Figure 10: Follow up of 3 years.

F.D.C. 36 years old. Operated in 2017

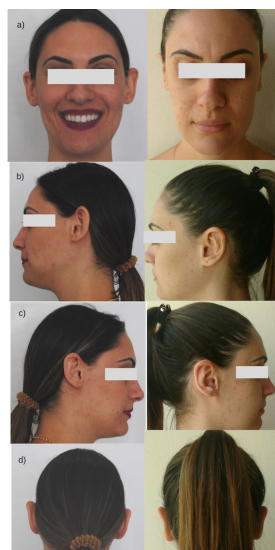


Figure 11: Follow up of 1 year.

L.R.M. 29 years old. Operated in 2017

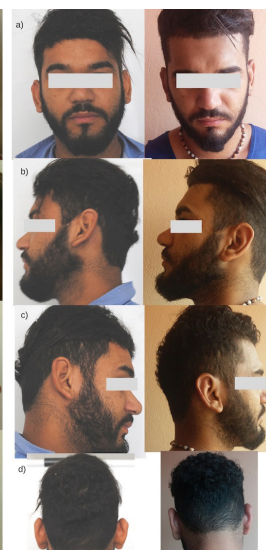

Figure 12: Follow up of 1 year.

Results

After a long observation of the 4.000 patients performed, the HPO Technique has proven to be capable of producing results by reducing surgical time to 45 minutes, to allow surgical procedure using sedation and local anesthesia from seven years old children, elimination of cartilage stitch needs, good aesthetic results due to condrotomy on cartilage islands with no stitches, minimum detachment at the ear concha, less pain and sensitivity loss, recurrence index less than 2%, infection index less than 0,1 %, patients satisfaction greater than 97%, reduced costs, fast recovery and return to normal activities, great repeatability and reproducibility, so becoming a powerful tool for the society self-esteem rescue.

Conclusion

The development of the HPO Technique has allowed reduction of the surgical time and final cost of the surgical procedure to around US 600,00 followed by many other advantages, like great repeatability and reproducibility, thus enabling access to a lot of number of citizens with their self-esteem rescued.

References

1. Francisco de Oliveira Goulart, Danilo Santos Vidal de Arruda, Bruno Menezes Karner, et al. Correção da orelha de abano pela técnica de incisão cartilaginosa, definição da antélice com pontos de Mustardé e fixação da cartilagem conchal na mastoide. Rev Bras Cir. Plást. 2011; 26: 602-607.
2. Bradbury ET, Hewison J, Timmons MJ. Psychological and social outcome of prominent ear correction in children. British Journal of Plastic Surgery. 1992; 45: 97-100.
3. Thorne CH, Wilkes G. Ear deformities, otoplasty and ear reconstruction. Plastic Reconstr Surg. 2012; 129: 701-716.
4. Young L, Young SK, Won JL, et al. Proposal of a Classification System for the Assessment and Treatment of Prominent Ear Deformity. Aesthetic Plast Surg. 2017; 42: 759-761.
5. Steven S, H Kent B, Decoding the DNA of the Toyota Production System. Harvard Business Review. 1999; 77: 97-107.
6. Gasques JA, Pereira de Godoy JM, Cruz EM. Psychological effects of otoplasty in children with prominent ears. Aesthetic Plast Surg 2008; 32: 910-914.
7. Peter A, Becky L Guy J. Otoplasty: Critical review of clinical results, The Laryngoscope.
8. Smittenberg MN, Marsman MS, Veeger NJGM, et al. Comparison of Cartilage-Scoring and Cartilage-Sparing Otoplasty: A Retrospective Analysis of Complications and Aesthetic Outcome of 1060 Ears, Plastic and Reconstr Surg. 2018; 141: 500-506.
9. Hendrickx BIMM, Hamdi M, Zeltzer A, et al. The 'WiFi' otoplasty: Combined concentric posterior microchondrectomies and sutures for correction of prominent ears. J Plast Reconstr Aesthet Surg. 2018; 71: 900-905.
10. Lam SM. Edward Talbot ElyFather of Aesthetic Otoplasty. Arch Facial Plast Surg. 2004; 6: 64.