

A Case Report of Amyand's Hernia in a 55-year-old Saudi Male

Ahmed Fathy Mustafa¹, Adel Ahmed Alfayez^{2*}, Abdulmajeed Mubarak Alshammari³ and Bayan Abdulkarim Alsamaan⁴

¹General Surgery Specialist, King Khalid Hospital, Hail-Saudi Arabia.

²Pediatric Surgery Resident, PSMMC, Riyadh-Saudi Arabia.

³General Surgery Resident, King Khalid Hospital, Hail-Saudi Arabia.

⁴Sixth year medical student, University of Ha'il-Saudi Arabia.

*Correspondence:

Adel Ahmed Alfayez, Pediatric Surgery Resident, PSMMC, Riyadh-Saudi Arabia.

Received: 18 January 2019; Accepted: 11 February 2019

Citation: Ahmed Fathy Mustafa, Adel Ahmed Alfayez, Abdulmajeed Mubarak Alshammari, et al. A Case Report of Amyand's Hernia in a 55-year-old Saudi Male. Clin Rev Cases. 2019; 1(1): 1-4.

ABSTRACT

Introduction: Amyand's hernia is a rare entity. Basically, means that the vermiform appendix is located within the hernial sac and its contents. The purpose of this report is to share our experience with healthcare community about similar rare events and to discuss the best modality approaches.

Presentation of Case: 55 years old male, complained of: Vomiting, abdominal distension followed by abdominal pain and absolute constipation. His condition becomes more progressive till he developed bilious vomiting and severe tense abdominal distension. He had history of exploratory laparotomy 40 years ago. On examination, there is a visible midline laparotomy scar along with right irreducible inguinal bulging, abdominal X-ray erect was taken and showed "multiple air fluids levels". Diagnosis of right obstructed inguinal hernia was made and he underwent right inguinal hernia repair. Infrequent findings were encountered during surgical course and managed based on recent guideline.

Discussion: A 55-year-old male, went through inguinal hernia repair with unexpected intraoperative findings. Although it's rare, but important to be discussed in relevant literatures. Amyand's hernia has variable types of presentations, with acute appendicitis may be faced. In our article, we discuss the pathogenesis, types of presentations and the incidence of A. hernia. Also, diagnostic modalities, recent management guidelines are discussed here.

Conclusion: Intraoperative findings of perforated vermiform appendix inside a hernial sac, is difficult to be assessed preoperatively. The article highlights the importance of considering unusual findings during surgery in patients who are going for hernia repair irrespective of their ages and presentations.

Keywords

Case report, Inguinal hernia, Unusual findings, Perforated vermiform appendix, Amyand's hernia.

Introduction

The work has been reported in line with the SCARE criteria [1]. Inguinal hernia repair is one of the commonest operations in surgical practice [2]. However, when a surgeon encounters unusual content it could pose a difficulty in its management. The surgeon may encounter unusual findings, such as a vermiform appendix partly or fully contained in the hernia sac, inflamed or non-inflamed, stretched or curved, and adhered or not adhered to the sac walls. The often-encountered unusual contents are appendix,

ovary, fallopian tubes, urinary bladder, meckel's diverticulum and sigmoid colon [3,4]. A normal or inflamed vermiform appendix found inside an inguinal hernia sac is called Amyand's hernia, in honor of the surgeon Claudius Amyand who first reported this interesting entity in 1735 [5]. Amyand's hernias usually present on the right side due the normal anatomic position of the appendix. In rare cases that can be associated with situs inversus, malrotations of the intestines and mobile caecum, an Amyand's hernia may appear on the left side [6]. Our patient was managed in a community governmental hospital.

Case Report

55 years old Saudi male, known to have Diabetes Mellitus. He

visited our ER department complained of:

Vomiting [6 days], abdominal distension followed by abdominal pain [4 days] and absolute constipation for [one day]. His condition becomes more progressive till he developed bilious projectile vomiting and severe tense abdominal distension. He mentioned history of exploratory laparotomy 40 years ago, with unknown reason. On examination patient looks unwell, was discomforted. Vitally stable. Abdominal examination revealed obviously distended abdomen with visible midline laparotomy scar. On palpation, there is right irreducible inguinal hernia and mild tenderness all over the abdomen. Auscultation revealed +ve bowel sounds [one minute]. Laboratory investigations revealed High amylase and high WBCs, high fasting blood sugar, others are within normal ranges. Radiological imaging including abdominal X-ray [Figure 1] and Abdominal CT with double contrast done in ER [Figures 2 and 3]. Based on our findings our final Diagnosis was "right obstructed inguinal hernia". So, patient was admitted on 03/01/2018, in which he underwent exploratory laparotomy with right inguinal hernia repair without mesh through right inguinal incision + adhesiolysis and appendectomy through lower midline incision by an experienced surgeon and assistants. Intraoperative, there were unusual findings of severe adhesions and perforated appendix within the herniated bowel with reactive pyogenic membrane from the inflamed & gangrenous appendix [Figure 4]. Appendix was sent to histopathology with gross appearance 8*1.5*1.5 cm, greyish brown in color appendix [Figure 5]. Postoperative wound was dry and clean with no signs of complications or infections. Patient was discharged on 13/01/2018 on stable condition with an OPD follow up in 2 weeks.

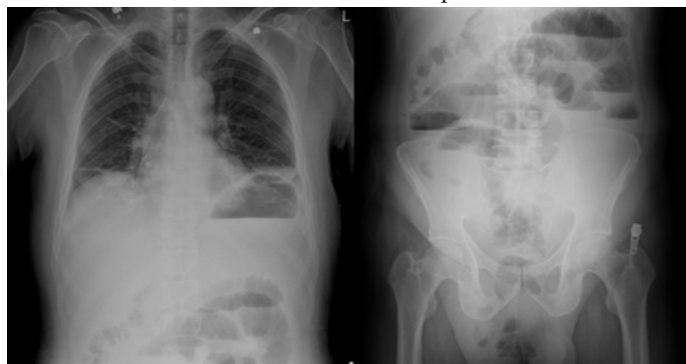


Fig 1. Multiple air-fluid levels seen in erect abdominal X-ray film.

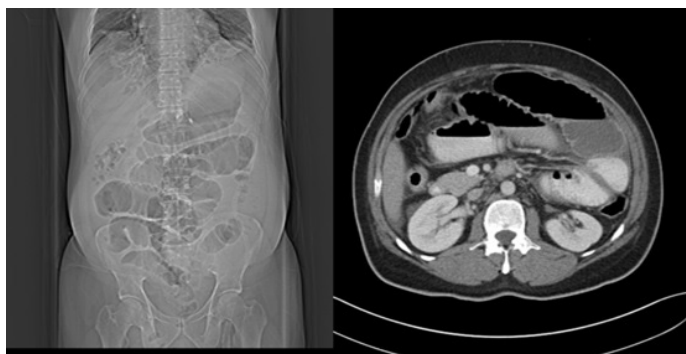


Fig 2. Dilated jejunal and proximal ileal loops seen in abdominal CT-Scan with multiple air-fluid levels.

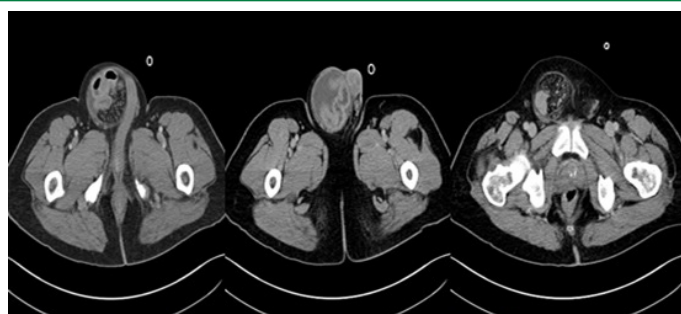


Fig. 3. There is evidence of protrusion of mesentery and small bowel loops seen in right inguino-scrotal hernia changes.

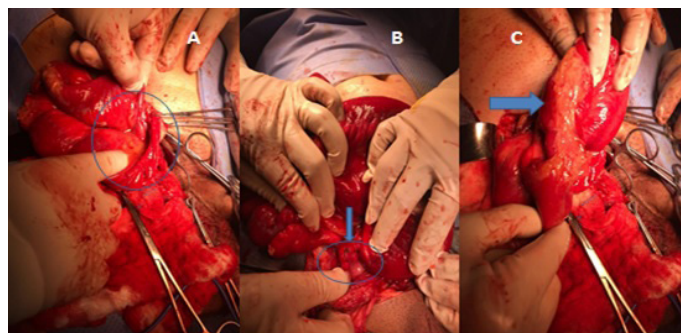


Fig. 4. A. Hernia contents and base of appendix was identified, B. perforated appendix seen, C. pyogenic membrane as a result of inflammation.

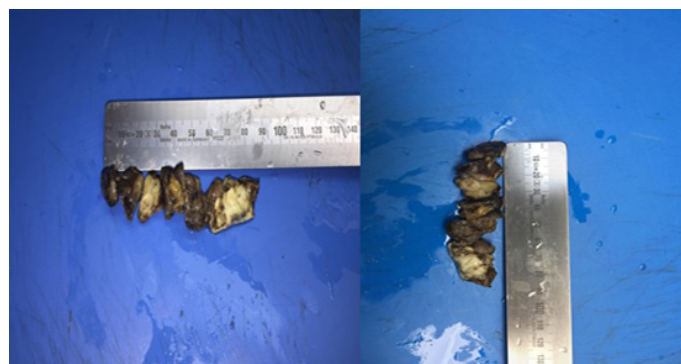


Fig. 5. gross appearance of the appendix.

Discussion

Although rare, a hernia sac may contain vermiform appendix and, exceptionally, acute appendicitis. De Garengot first reported this finding in a femoral hernia sac [7], in 1731. Subsequently, a voluminous literature evolved in which anatomists and surgeons recorded the availability of the appendix within the hernia sac. Inguinal hernia has no preference for age group or sex; there are cases of Amyand hernia reported in the range from a neonatal period to 92 years old [6]. It has an incidence that varies from 0.19 to 1.7% [8,9] and it's diagnosed during hernioplasty, more commonly in children because of a patent vaginal process. Literature review reports a perforated appendix in 0.1%, with mortality range from 15 to 30% because of severe abdominal sepsis [8-10]. The probability of an individual to have acute appendicitis at some point in his life is about 8% [11]. The incidence of a non-inflamed appendix within adult inguinal hernias is about 1%. The case of an inflamed,

perforated appendix or peri appendicular abscess within an inguinal hernia in adults is much lower and accordingly to different studies ranges between 0.13% and 1% [12,13], regardless of the stage of presentation. The pathophysiology is unfamiliar. When the appendix enters the sac, it becomes susceptible to trauma due to external force or due to contraction of the abdominal muscles. Thus, the compressed appendix can get injured and inflamed [14]. Mobile cecum may be a predisposing factor for developing Amyand's hernia [15]. An Amyand's hernia is virtually always diagnosed intraoperatively. Computer tomography with contrast can be diagnostic [16]. Inguinal hernias are mostly diagnosed with history and clinical examination. Ultrasonography (USG), computed tomography scan, magnetic resonance imaging, or color Doppler is never carried out in the preoperative period, but if done, these investigations are very useful to confirm the presence of unusual organs as well as their vascularity in case of strangulated hernias [17]. However, it is rarely used since such a hernia usually mimics either a simple reducible or an incarcerated inguinal one and is therefore admitted for elective or emergency surgery respectively, without using any prospective imaging techniques. Our patient wasn't diagnosed pre-op as amyand's hernia and we did the surgery based on imaging findings of obstructed hernia, in which we had this incidental finding. The clinical presentation of an Amyand's hernia usually mimics a strangulated inguinal hernia and therefore the vast majority of these cases are not diagnosed preoperatively. In fact, there are very few cases of preoperatively diagnosed Amyand's hernias in literatures [18].

The differential diagnosis may include strangulated hernia, Richter's hernia, orchitis, omentocoele, inguinal lymphadenitis, epididymitis and hemorrhagic testicular tumor [19]. The management of Amyand's hernias is still a subject of debate and should be individualized depending on the operative findings and co-morbidity factors. The most widely accepted classification that epitomizes operative findings and management is the one by Losanoff and Basson which describes 4 distinct types [table.1] [20].

Classification	Description	Surgical management
Type 1	Normal appendix in an inguinal hernia	Hernia reduction, mesh Repair, appendectomy in young patients
Type 2	Acute appendicitis in an inguinal hernia, without abdominal sepsis	Appendectomy, primary repair of hernia without mesh
Type 3	Acute appendicitis in an inguinal hernia, with abdominal wall or peritoneal sepsis	Laparotomy, appendectomy, primary repair without mesh
Type 4	Acute appendicitis in an inguinal hernia, with abdominal pathology	Manage as Type 1–3, investigate pathology as needed

Table 1: Losanoff and Basson classification of Amyand's hernia.

Our patient had a Type 3 Amyand's hernia and he underwent an exploratory laparotomy and inguinal hernia repair without mesh + appendectomy.

Conclusion

- Every surgeon should be prepared for the possibility of coping with such an unexpected situation.
- Amyand's hernia is a rare type of inguinal hernia that can sometimes lead to serious and life-threatening complications due to peritoneal spread of the septic process and should therefore be faced with utmost vigilance.
- The best management option is described by Losanoff and Basson classification.
- This case demonstrates that this pathology must remain in the mind of the surgeons especially in the event of a strangulated hernia and offer a comprehensive review.

Acknowledgement

I express my sincere respect and gratitude to my colleague at histopathology lab Mr. Bandar Alsaif "Laboratory Technician" who has given his valuable support and cooperation to successfully complete this useful paper.

References

1. Agha RA, Fowler AJ, Saetta A, et al. The SCARE Statement: Consensus-based surgical case report guidelines. *International Journal of Surgery*. 2016.
2. Lau H. Inguinal hernia repair: the impact of ambulatory and minimal access surgery. (Thesis). University of Hong Kong, Pokfulam, Hong Kong SAR. 2002.
3. Gurer A, Ozdogan M, Ozlem N, et al. "Uncommon Content in Groin her-nia Sac," *Hernia*. 2006; 10: 152-155.
4. Ballas K, Kontoulis T.H, Skouras C.H, et al. "Unusual Find-ings in Inguinal Hernia Surgery. Report of 6 Rare Cases," *Hippokratia*. 2009; 13: 169-171.
5. Amyand C. Of an inguinal rupture, with a pin in the appendix caeci, incrusted with stone; and some observations on wounds in the guts. *Philosophical Transactions of the Royal Society of London*. 1736; 39: 329-336.
6. Ghafouri A, Anbara T, Foroutankia R. A rare case report of appendix and cecum in the sac of left inguinal hernia (left Amyand's hernia). *Med J Islam Repub Iran*. 2012; 26: 94-95.
7. Akopian G, Alexander M. de Garengot Hernia: Appendicitis within a femoral hernia. *Am Surg*. 2005; 71: 526-527.
8. Ivashchuk Galyna, et al. Amyand's hernia: a review. *Med Sci Monit*. 2014; 20: 140e6.
9. Michalinos A, Moris D, Vernadakis S. Amyand's hernia: a review. *Am J Surg*. 2014; 207: 989e95.
10. Samani RS, et al. Amyand's hernia: an extremely rare condition of inguinal hernia accompanied with acute appendicitis. *Ann Colorectal Res* 2014; 2: e17748.
11. Sengul I, Sengul D, Aribas D. An elective detection of an Amyand's hernia with an adhesive caecum to the sac: Report of a rare case. *N Am J Med Sci*. 2011; 3: 391-393.
12. Ryan WJ. Hernia of the vermiform appendix. *Ann Surg*. 1937; 106: 135-139.
13. Carey LC. Acute appendicitis occurring in hernias: a report of 10 cases. *Surgery*. 1967; 61: 236-238.
14. Apostolidis S, Papadopoulos V, Michalopoulos A, et al. Amyand's hernia: a case report and review of literature. *The*

-
- Internet J Surgery. 2005; 6.
15. Kwok CM, Su CH, Kwang WK, et al. Amyand's hernia a case report and review of literature. Case Rep Gastroenterol. 2007; 1: 65-70.
 16. Luchs JS, Halpern D, Kats DS. Amyand's hernia: Prospective CT diagnosis. J Comput Assist Tomogr. 2000; 24: 884-886.
 17. Sunder Goyal, Madhuri Shrivastva, Verma RK, et al. Uncommon Contents of Inguinal Hernial Sac: A Surgical Dilemma. Indian J Surg. 2015; 77: S305-S309.
 18. Quartey B, Uguchukwu O, Kuehn R, Ospina K. Incarcerated recurrent Amyand's hernia. J Emerg Trauma Shock. 2012; 5: 344-346.
 19. Torino G, Campisi C, Testa A, Baldassarre E, Valenti G. Prosthetic repair of a perforated Amyand's hernia: hazardous or feasible? Hernia. 2007; 11: 551-552.
 20. Losanoff JE, Basson MD: Amyand hernia: a classification to improve management. Hernia 2008; 12: 325-326.